

Effect of Tokay Gecko (*Gekko gekko* LINNAEUS, 1758) Saliva on Angiogenesis During Wound Healing Phase of Autotomized Tail in Common Sun Skink (*Eutropis multifasciata* KUHL, 1820)
(Pengaruh Saliva Tokek (*Gekko gekko*, LINNEAUS 1758) Terhadap Angiogenesis Pada Fase Penyembuhan Luka Ekor Kadal Kebun (*Eutropis multifasciata* KUHL, 1820) Setelah Autotomi)

Nurul Inayah^{1,2}, Nyoman Puniawati Soesilo² & Rarastoeti Pratiwi³

⁽¹⁾Zoology Division, Research Center for Biology-Indonesian Institute of Sciences (LIPI)
^(2,3) Faculty of Biology, Gadjah Mada University
Email: nurulinayah.as@gmail.com

Received: December 2016, Accepted: June 2017

ABSTRACT

The purpose of this study was to investigate the effect of Tokay gecko saliva on morphology and angiogenesis response on the healing process of skink tail wound and also to characterize the protein profile of *Gekko* saliva. Twelve skinks were autotomized and wound surface of tail smeared by young gecko saliva, adult gecko saliva, and human's saliva twice per day and control. The morphological changes of the wound surface were observed. The angiogenesis response was observed in vitro using Chorioallantois Membrane (CAM) of the ninth day's chick embryos. Protein profile of gecko saliva analyzed with SDS-PAGE. Generally, treated wound showed a better healing. Young gecko saliva able to stimulate angiogenesis in wound healing stage of sun skink tail after autotomy. Saliva protein of young and adult *Gekko* differences was not only in the size (or density) but also in the number of the bands. The young and adult *Gekko* revealed a striking consistency of protein patterns, indicating a profound physiological stability of the whole saliva. This study showed that *Gekko* saliva able to accelerate wound healing, thus *Gekko* saliva may have potential me as a future therapeutic for treating infected wounds.

Keywords: Tokay gecko saliva, wound healing, sun skink tail, angiogenesis, protein profile.

ABSTRAK

Tujuan penelitian ini adalah untuk mempelajari pengaruh ludah tokek terhadap morfologi dan respon angiogenesis pada penyembuhan luka ekor kadal, serta untuk mengetahui profil protein ludah tokek. Dua belas ekor kadal diautotomi dan permukaan luka diolesi dengan ludah tokek muda, ludah tokek dewasa, ludah manusia dua kali sehari, dan kontrol. Perubahan morfologi permukaan luka ekor diamati. Respon angiogenesis diamati secara in vitro menggunakan Membran Korioalantois (MKA) embrio berumur 9 hari. Profil protein ludah tokek dianalisis menggunakan SDS PAGE. Secara umum, penyembuhan luka pada kelompok perlakuan lebih baik daripada kontrol. Tokek muda mampu memicu angiogenesis pada penyembuhan luka ekor kadal. Perbedaan pita protein ludah tokek muda dan dewasa tidak hanya pada ukuran (densitas) tetapi juga berbeda dalam jumlah pita. Konsistensi pola protein ludah tokek muda dan dewasa menunjukkan kestabilan fisiologi pada saliva. Studi ini menunjukkan bahwa ludah tokek dapat mempercepat penyembuhan luka, sehingga ludah tokek memiliki potensi sebagai obat untuk menyembuhkan luka infeksi.

Kata Kunci: Ludah tokek, penyembuhan luka, ekor kadal, angiogenesis, profil protein.

INTRODUCTION

Wound licking has been shown to advance wound healing among humans and many other animals (Abbasian *et al.* 2010). Animal licking behavior can promote wound healing because of contact with saliva. In China, tokay gecko used as a traditional medicine for inflammation, allergic response, irritation, and acute wound (Liu *et al.* 2008). During wound healing need angiogenesis (Tonessen 2000). Angiogenesis is

the growth of new blood vessels from pre-existing capillaries (Chapulia *et al.* 2004;).

Angiogenesis occurs when there is a compound that stimulates angiogenesis (proangiogenic) (Kerbel 2008). Epidermal growth factor (EGF), nerve growth factor (NGF), and histatin are growth factors which have a role in stimulating wound healing (Jarrar & Taib 2004). Secretory leukocyte protein inhibitor (SLPI) also play an important role in the wound healing of skin (Abbasian *et al.* 2010).

Common sun skink is one of the Lacertilians which is able to regenerate its tail after autotomy (Hughes & Dennis 1959; Soesilo 2002; Mausfield *et al.* 2003; Maginnis 2006; and Gillis *et al.* 2009). Tail autotomy followed by regeneration so that it grows a new tail that has a size and shapes similar to the original tail (Kamrin & Singer 1955; Soesilo 1992; Downes & Shine 2001) but different in anatomical structure especially the vertebrae, nerve tissue, and skin (Balinsky 1970). The spinal cord of sun skink tail in wound healing phase able to stimulate angiogenesis (Soesilo 2002). Anatomical studies on the saliva of vertebrates have mainly been concerned with mammals, whereas little attention has been paid to the saliva of non-mammalian vertebrates.

Chung *et al.* (2017) studied that peptide from the plasma of Komodo promotes wound healing. The previous study also investigates *Gecko* powder as an anti-tumor drug (Liu *et al.* 2008), but few anatomical studies have been carried on this *Gecko* saliva. EGF and NGF concentration in rat saliva 100 times higher than in human saliva (Oudhoff *et al.* 2008). According to Brand & Veerman (2013), EGF and NGF in human saliva higher than in human plasma. Therefore, probably growth factor in *Gecko* saliva can play a similar role in lizard as it does in mice and rats. This study was aimed to investigate the effect of *Gecko* saliva on the healing process of sun skink tail wounds and also to characterize the protein profile of *Gecko* saliva.

MATERIALS AND METHODS

Twelve adult sun skinks were used and divided into four groups (wound of the stump treated with young gecko saliva (P1), adult gecko (P2), human saliva (P3) twice per day and untreated wound (P0). The morphological changes of the regenerated tails were observed. Angiogenesis response was observed in vitro using twelve Chorioallantoic Membranes (CAM) of developing chick embryo (Leng *et al.* 2004). Tail regenerates of 1,2,3, and 4 days were implanted to CAM. The implanted eggs were incubated for 72 hours at 37.5°C and opened to observe the vascularization around

the implant as an indication of angiogenesis response. Angiogenesis response was calculated from the number of blood vessel toward implant (Soesilo 2002). ANOVA used to analysis whether there was any influence of saliva treatment to wound healing.

Saliva was collected from healthy adult human (female), young and adult gecko. Saliva samples (50ul) were mixed with *Gecko* loading buffer (60 ml aquabides & 22,5 ml of 0,5 M Tris-HCl, pH 6,8), 10% *glycerol*, 10% SDS, 5% mercaptoethanol 2-β, and 0,001% *bromophenol blue*). Samples were centrifuged for 5 seconds then heat at 95°C for 5 min. Prepared samples were analyzed by SDS-PAGE using the 12,5% resolving gel and 3% stacking gel (Schwartz *et al.* 1995). Three samples were loaded in one gel. Molecular weight marker (Bio-Rad, California, USA) were used in the gel.

Electrophoresis was done at 100 V for around 3–4 h and it was removed for staining using the Coomassie staining, then destained gradually with several changes of destaining solution (Methanol, Acetic acid, Isopropanol, and aquabides) for 3 hours until bands showed the appropriate color. Saliva proteins were identified according to their relative mobility in gel and stain patterns following the criteria described by Banderas-Tarabay *et al.* (2002).

RESULTS

The wound of sun skink tail immediately after autotomy not followed by loss of blood because arteries and veins on the plane of autotomy have musculus sphincter which closes when autotomy occurs. Morphologically, in normal conditions (without treatment), wound healing occurs 5-6 days after autotomy then followed by dedifferentiation and proliferations of tissue to form the blastema (8-10 days after autotomy). In this study, the wound healing of treated wound was faster (3 days after autotomy) than the control one (Table 1)

Chorioallantoic Membrane showed the presence of numerous vertically growing blood vessels into the spinal cord implant as an indication of angiogenic ability (Figure 2). The highest angiogenesis response occurs on wound healing phase three days after autotomy, then

Tabel 1. Gecko saliva effect on wound closure of the tail stump (0-8 days after autotomy).

Day after autotomy	Treatment	Morphology					
		Septum interadiposum		Wound			
0	Control	visible		damp			
	P1	visible		damp			
	P2	visible		damp			
	P3	visible		damp			
1-2	Control	visible		damp			
	P1		not visible	damp			
	P2		not visible	damp			
	P3	visible		damp			
3-4	Control	visible		damp			
	P1		not visible		dry	closed	formation a scab
	P2		not visible		dry		
	P3	visible		damp			
5-6	Control	visible		damp			
	P1		not visible			closed	formation blastema
	P2		not visible		dry		
	P3	visible		damp			
7-8	Control	visible		dry			
	P1		not visible			closed	formation blastema
	P2		not visible		dry	closed	formation a scab
	P3	visible		dry			

Remarks: C: control, P1: wound treated with young gecko saliva, P2: wound treated with adult gecko saliva, and P3: wound treated with human saliva

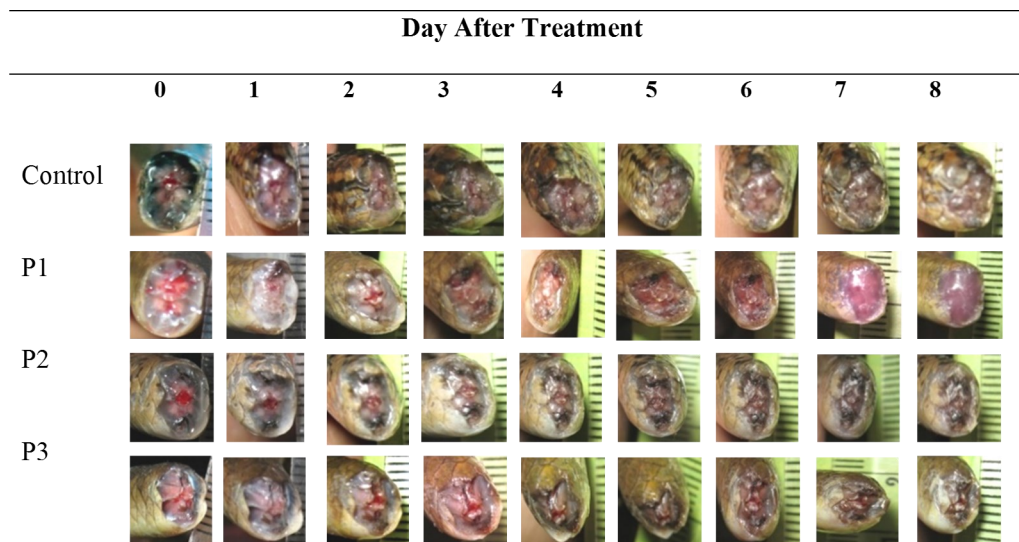


Figure 1. The wound surface of sun skink tail (0-8 days after autotomy), C: control, P1: wound treated with young gecko saliva, P2: wound treated with adult gecko saliva, and P3: wound treated with human saliva

declined and are likely to remain at 4 days after autotomy see (Figure 3).

The average number of the new blood vessel is significantly different between the treated wound and the control one (Tabel 2). On the 1-4 days wound healing phase, the number of blood vessel were higher in the treated wounds than the control ones.

The visual inspection of the gels electrophoreses revealed 13 bands for gecko saliva and 11 bands for human saliva. Some bands were dark blue; others stained light blue. The bands ranged in density from extremely faint, to narrow but distinct, to those which were thick and heavily stained (Figure 4). Each profile showed characteristic bands (A, B, & C). Saliva of both

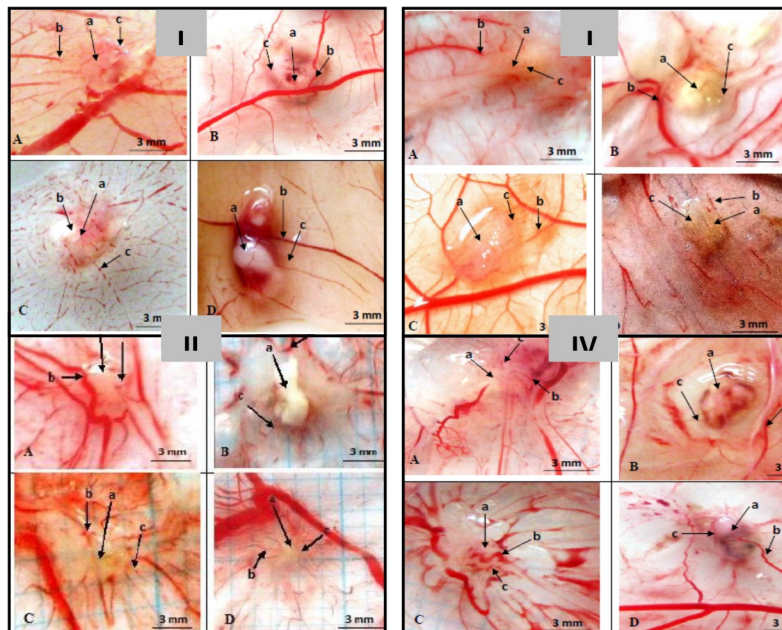


Figure 2. The angiogenesis response on the CAM with spinal cord implant in wound healing phase 1-4 days after autotomy (I, II, III, IV). Spinal cord implant without saliva (A), implant treated with young gekko saliva (B), adult gekko saliva (C), and human saliva (D). The implant (a), the main vessel in CAM (b), and new blood vessels toward implant (c).

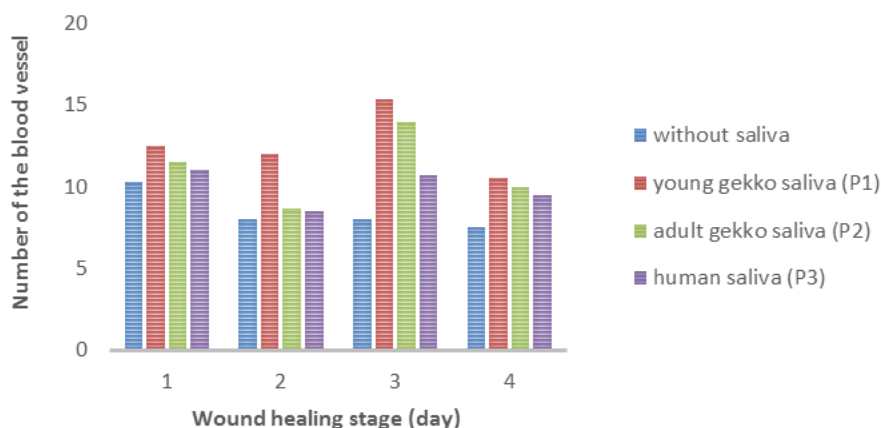


Figure 3. Angiogenesis responses on CAM after a spinal cord implantation Blood vessel in wound healing phase 1-4 days after autotomy.

young and adult gekko was consistent showing the specific protein about 59 kDa and 46 kDa (A59 & B46) in the same locus, but it was not detected in the human saliva. Otherwise, the specific protein about 33 kDa detected in human saliva but did not found in *Gekko* saliva.

The heaviest concentration of proteins was found in the upper one-third of the gel (A59). This region above 50 kDa, showed one band migrated with the ovalbumin standard. According to Schwartz *et al.* (1995) lactoferrin

has molecular weight 97 kDa, while the molecular weight of both lysozyme and Proline-rich Protein (PRP) were below 29 kDa. Both saliva of young and adult gekko saliva have a similar pattern but the band's concentration was different.

DISCUSSION

The entire period of tail regeneration of sun skink has been divided histologically into five

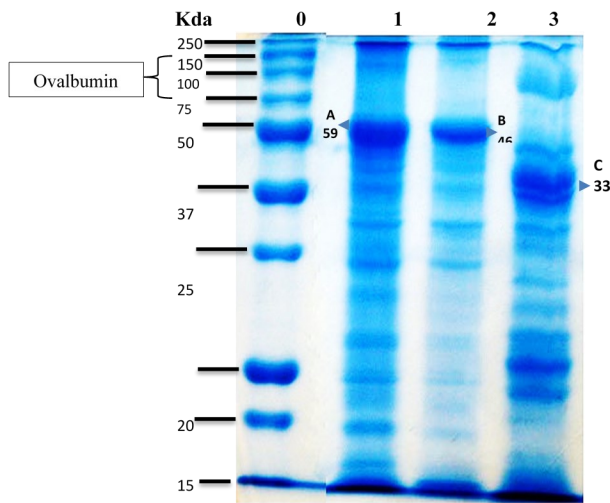


Figure 4. Lane 0 represents the molecular weight markers. Lane 1,2, and 3 represents proteins present in 5µl of processed saliva. Proteins were separated by SDS-PAGE in a Criterion 12,5% Tris-HCl gel and stained with Bio-Safe Coomassie stain. Gel shown is the actual size.

different stages; stage I; wound-healing stage and dedifferentiation (5-6 days), stage II; the phase of blastema accumulation and blastema growth (5-11 days). Stage III is the phase of differentiation and morphogenesis of the regenerate (Iten & Bryant 1976; Soesilo 2002). However, the process of regeneration is, in fact, a continuous one (Karim & Michael 1993).

A variety of biologic substances able to accelerate wound healing (Abbasian *et al.* 2010). Saliva contains numerous bioactive molecules which were classified according to their various functions: lubrication, antimicrobial activity, antioxidant activity, inflammatory,

immune responses and wound healing (Ohshima *et al.* 2002). Saliva of house gecko (*Ptyodactylus hasselquistii*) contains hyaluronidase, sialidase, and glycoprotein (Jarrar & Taib 2004). Liu *et al.* (2008) investigated that Gecko has anti-tumor effects on human esophageal carcinoma cell lines. Furman (2012), studied the venom of the Gila monster (*Heloderma suspectum* COPE, 1869) as an anti-diabetic agent. He found exendin-4 occurs naturally in the saliva of the Gila monster able to increase the production of insulin when blood sugar levels are high.

Several numbers of substantial growth factor have been identified in human and animal saliva. Some of this growth factor are present in a concentration that has biological activity in vitro and in vivo, therefore potentially could play an important role in the oral and in the promotion of healing of oral or cutaneous wounds (Brand & Veerman 2013). Epidermal growth factor (EGF), nerve growth factor (NGF), and histatin are stimulating wound healing including proliferation, differentiation, and cell migration (Jarrar & Taib 2004). Epidermal growth factor binds like the other growth factors, to a specific receptor on the membrane of the target cell, initiating a cascade of processes. This result in migration, proliferation, and differentiation of cells (Brand & Veerman 2013). Migration and proliferation of epithelial cell are activities in the initial stages of wound healing (Kang *et al* 2008; Siger & Clark 1999). Transforming growth factor-alpha (TGF-α), insulin, insulin-like growth factors I and II (IGF-I, IGF-II), transforming factor-beta (TGF-β), vascular endothelial growth factor (VEGF) and basic fibroblast

Table 2. The average number of new blood vessel toward the implant of the sun skink tail spinal cord of wound healing phase of 1-4 days after autotomy.

Day	Without saliva (C)	Young <i>Gecko</i> saliva (P1)	Adult <i>Gecko</i> saliva (P2)	Human saliva (P3)
1	10.33±2.08 ^e	12.5± 6.36 ⁱ	11.5±3.53 ^g	11± 0.00 ^f
2	8 ±2.83 ^b	12± 2.83 ^h	8.67±3.51 ^b	8,5± 0.71 ^b
3	8 ± 0.00 ^b	15.33± 1.15 ^k	14±1.41 ^j	10,67± 2.89 ^e
4	7.5±3.54 ^a	10.5±2.12 ^b	10±7. 07 ^d	9,5± 0.71 ^c

Remarks: a-k indicate significant differences (P < 0.05) within columns C, P1, P2, and P3.

growth factor (bFGF) help in reconstitution and healing of injured area (Hu *et al.* 2006; Lyons *et al.* 2010). Secretory leukocyte protein inhibitor (SLPI) also play an important role in the wound healing of skin (Abbasian *et al.* 2010).

This study investigated the effects of tokay gecko saliva on angiogenesis during wound healing phase of the autotomized tail in common sun skink. Three days after autotomy, morphologically, the wound treated with young *Gecko* saliva showed a better healing. It is probably because the protein in the saliva of young gecko higher than it has saliva of adult gecko and human, as Chauncey *et al.* (1987) suggested that the concentration of protein, sodium and chloride concentrations also osmolality values in the saliva decline with age. Thus wound closure in treated wound dried faster than the control as Alibardi (2010) suggested that after 2 days post-amputation in tail stumps, numerous granulocytes are accumulated over the stump, and participate in the formation of the scab.

On the 3rd day after autotomy, angiogenesis response higher in the treated wound than control ones. During wound healing, angiogenic capillary sprouts invade the fibrin/fibronectin-rich wound clot and within a few days organize into a microvascular network throughout the granulation tissue. As collagen accumulates in the granulation tissue to produce a scar, the density of blood vessels diminishes (Tonnesen *et al.* 2000). According to Soesilo (1992), 2-3 days after autotomy epithelial cells proliferate then migrates to the surface of the wound. During proliferation, some cells are in a state of mitosis. It indicates that wound closure occurs due to skin epithelial migration that previously had mitotic proliferation. On the eighth day after autotomy, treated wounds (P1) showed the formation of a blastema, while the other groups not formed yet. Our findings provided evidence that gecko saliva had a biological ability to accelerate wound healing and stimulate angiogenesis in treated wound of sun skink tail.

ACKNOWLEDGMENTS

The authors gratefully acknowledged Mulyati, M.Si for guides and helpful discussions, Suwardi and Ikhwan for technical support.

REFERENCES

- Abbasian, B., S. Azizi, & A. Esmaceli. 2010. Effects of Rat's Licking Behavior on Cutaneous Wound Healing. *Iranian Journal of Basic Medical Sciences* 13(1): 242-247.
- Alibardi, L. 2010. Ultrastructural Features Of The Process Of Wound Healing After Tail And Limb Amputation in Lizard. *Journal of Acta Zoologica*. 91: 306–318.
- Balinsky, BI. 1970. An Introduction to Embryology. W.B. Saunders Company. Philadelphia: 642-643
- Banderas-Tarabay, J.A., IGZD'. Oleire, RG. Estrada, EA. Luna, & M.G. Bagné. 2002. Electrophoretic Analysis of Whole Saliva and Prevalence of Dental Caries. A Study in Mexican Dental Students. *Journal of Archives of Medical Research* 33: 499–505
- Brand, H & ECI. Veerman. 2013. Saliva and Wound Healing. *The Chinese Journal of Dental Research*. 16(1):7-12.
- Chapulia RM., AR. Quesada & MM. Ángel . 2004. Review Angiogenesis and signal transduction in endothelial cells. *Journal Cell Molecular of Life Science*. 61: 2224–2243
- Chauncey, HH., RP. Feller & KK. Kapur. 1987. Longitudinal Age-Related Changes in Human Parotid Saliva Composition. *Journal of Dental Research*. 66 (2): 599-602
- Chung, EMC., SN. Dean, CN. Propst, BM. Bishop & ML. van Hoek. 2017. Komodo Dragon-Inspired Synthetic Peptide DRGN-1 Promotes Wound-Healing of a Mixed-Biofilm Infected Wound. *Natur Journal Partner Biofilm and Microbiomes* 9: 1-12.
- Downes, S. & R. Shine. 2001. Why Does Tail Loss Increase a Lizard's Later Vulnerability to snake predators?. *Journal of Ecology*. 82(5): 1293–1303
- Furman, BL. 2012. The development of Byetta (exenatide) from the Venom of the Gila monster as an Anti-Diabetic Agent . *Journal of Toxicon* 59: 464–471
- Gillis, GB., LA. Bonvini, & DJ. Irschick. 2009. Losing stability: tail loss and jumping in the arboreal Lizard, *Anolis carolinensis*.

- Journal of Experimental Biology*. 212: 604-609
- Hughes, A. & N. Denis. 1959. Tail Regeneration in the Geckonid Lizard, *Sphaerodactylus*. *Journal Embryology and Experimental Morphology*. 7(3): 281-302.
- Hu S, Li Y, Wang J, Xie Y, Tjon K, & Wolinsky L. 2006. Human saliva proteome and transcriptome. *Journal of Dental Research*. 85:1129-1133
- Iten, LE., & Bryan, SV. 1976. Stages of Tail Regeneration in the Adult Newt, *Notophthalmus viridescens*. *Journal of Experimental Zoology*. 196: 283-292
- Jarrar, BM. & NT.Taib. 2004. Histochemical Characterization of the lingual Salivary Glands of the House Gecko, *Ptyodactylus hasselquistii* (Squamata:Gekkonidae). *Journal of Asiatic Herpetological Research*. 10: 176-181
- Kamrin, RP. & M. Singer. 1955. The Influence of The Spinal Cord in the regeneration of The Tail Lizard, *Anolis Carlinensis*. *Journal of Experimental Zoology*. 128: 611-627.
- Karim, AEA. & MI. Michael. 1993. Tail Regeneration After Autotomy in the Geckonid Lizard *Bunopus tuberculatus*. *Journal of Qatar University Science*. 13 (2): 293-300
- Kang D, TH.Choi, K. Han, D. Son, JH. Kim, SH. Kim, J. Park. 2008. Regulation of K⁺ Channels May Enhance Wound Healing in the Skin. *Journal of Medical Hypotheses*. 71:927-929.
- Kerbel, RS. 2008. Molecular Origins of Cancer Tumor Angiogenesis. *Journal of New England of Medicine*. 358: 19
- Leng, T., MSJM. Miller, BSKV. Bilbao, MDDV. Palanker, P. Huie, & MS. Blumenkranz. 2004. The Chick Chorioallantoic Membrane As A Model Tissue For Surgical Retinal Research And Simulation. *Journal of Retinal and Vitreous Disease*. 24(3): 427-434
- Liu, F., GW. Jian, SY. Wang, Y. Li, YP. Wu, and SM. Xi.. 2008. Antitumor effect & mechanism of Gecko on human esophageal carcinoma cell lines in vitro and xenografted sarcoma 180 in Kunming Mice. *Journal of Gastroenterology*. 7. 14 (25): 3990-3996
- Lyons, JM., JE. Schwimer, CT. Anthony, JL. Thomson, JD. Cundiff, DT. Casey, C. Maccini, P.Kucera, YZ. Wang, JP. Boudreaux, & EA. Woltering. 2010. The Role of VEGF Pathways in Human Physiologic and Pathologic Angiogenesis. *Journal of Surgical Research*. 159: 517-527
- Maginnis, T.L. 2006. Review The Costs Of Autotomy And Regeneration In Animals: A Review and Framework For Future Research. *Journal of Behavioral Ecology*. 17:857-872
- Mausfield, P. & A. Schmidt. 2003. Molecular phylogeography, intraspecific variation, and speciation of the Asian scincid sun skink genus *Eutropis* Fitzinger, 1843 (Squamata: Reptilia: Scincidae): taxonomic and biogeographic implications. *Journal of Organism Diversity & Evolution*. 3(3): 161-171
- Ohshima M., M. Sato, M. Ishikawa, M. Maeno, K. Otsuka. 2002. Physiologic Levels of Epidermal Growth Factor in Saliva Stimulate Cell Migration of an Oral Epithelial Cell Line, HO-1-N-1. *Journal of European Oral Science*. 110:130-136.
- Oudhoff , MJ., JGM. Bolscher, K. Nazmi, H. Kalay, WV. Hof, AVN. Amerongen, & ECI. Veerman. 2008. Research Communication Histatins are The Major Wound-Closure Stimulating Factors in Human's saliva As Identified in a Cell Culture Assay. *Journal of FASEB*. 22: 3805-3812.
- Singer, AJ. & RAF. Clark. 1999. Cutaneous Wound Healing. *Journal of the New England of Medicine* 341(10): 738-746
- Soesilo, NP. 1992. Proses Regenerasi Ekor Kadal (*Mabouya multifasciata* Kuhl.). *Berkala Ilmiah Biologi*. 1(4): 169-175
- Soesilo, NP. 2002. Pengaruh Regenerat Ekor Kadal (*Mabouya multifasciata* Kuhl.) Terhadap Angiogenesis. *Berkala Ilmiah Biologi*. 2(14): 833-843
- Swartz, SS., WX. Zhu & LM. Sreebny. 1995. Sodium Dodecyl Sulphate-Polyacrylamide Gel Electrophoresis of Human Whole

Saliva. *Journal of Archives of Oral Biology*. 40(10): 949-958

Tonnesen, MG, X. Feng, & RAF. Clark. 2000. Angiogenesis in Wound Healing. *Journal of Investigative Dermatology Symposium Proceedings*. 5(1):40-46